

# Neonatal transient myasthenia gravis and a case with intestinal perforation

Mervan Bekdas<sup>1</sup>, Huseyin Altunhan<sup>1</sup>, Sevil Göksügür<sup>1</sup>, Hulya Ozturk<sup>2</sup>, Fatih Demircioglu<sup>1</sup>

<sup>1</sup>Department of Pediatrics, Abant Izzet Baysal University Faculty of Medicine, Bolu, Turkey.

<sup>2</sup>Department of Pediatric Surgery, Abant Izzet Baysal University Faculty of Medicine, Bolu, Turkey.

Correspondence to: Mervan Bekdas, E-mail: vanbek@gmail.com

Received August 24, 2014. Accepted January 27, 2015

## Abstract

Transient neonatal myasthenia gravis (MG) is observed in babies born to mothers with MG. Hypotony and respiratory distress are the most important warning signs observed in these babies. Anticholinesterases are used in the treatment. In this study, we present a case diagnosed with transient neonatal MG that has developed intestinal perforation after neostigmine treatment.

**KEY WORDS:** Myasthenia gravis, neonatal, intestinal perforation

## Introduction

Transient neonatal myasthenia gravis (MG) is a postsynaptic neuromuscular transmission disorder, and it is observed in 10%–15% of the babies born to mothers with MG.<sup>[1]</sup> It is caused by maternal anti-acetylcholine receptor antibodies with IgG character that passively pass from the placenta. Clinical symptoms such as feeding difficulty, inadequate respiration struggles, and hypotony reveal within the first 3 days after birth and continue for up to 1–6 weeks. Anticholinesterases are frequently used in the treatment.<sup>[2]</sup>


Intestinal perforation observed in premature babies is generally caused by spontaneous intestinal perforation and necrotizing enterocolitis.<sup>[3]</sup> However, the transient neonatal MG is an extremely rare cause when etiology of intestinal perforation is taken into consideration. In this study, we aimed to present a case of an infant born to a mother with

MG, who developed intestinal perforation after neostigmine treatment.

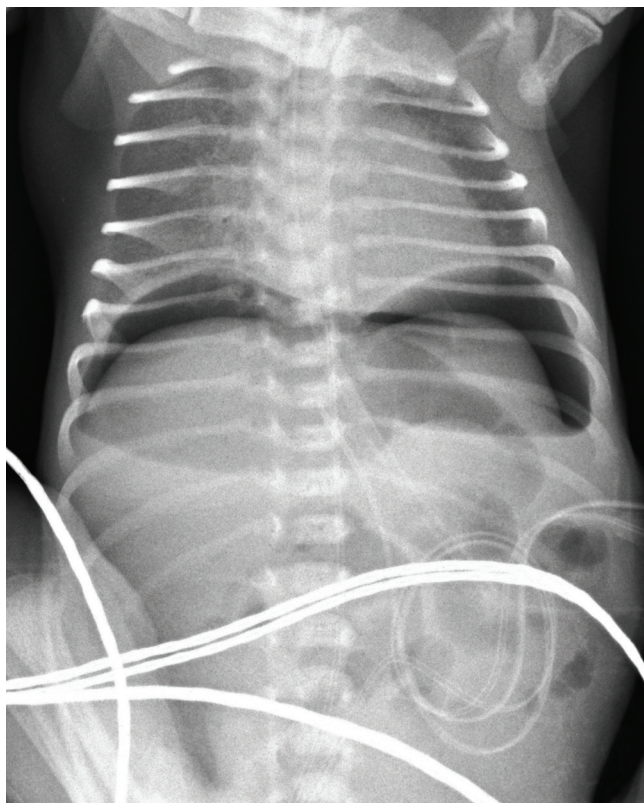
## Case Report

A 2280 g female infant was born by cesarean delivery at 31 weeks of gestation to a 27-year-old mother with MG. Baby was shifted to newborn intensive care unit for hypotonia, tachypnea, and intercostal retractions starting after birth. The physical examination and chest X-ray were consistent with respiratory distress syndrome. The baby received exogenous surfactant (beractant 100 mg/kg) and was ventilated on synchronized intermittent mandatory ventilation mode. Neostigmine test was performed on the baby to facilitate separation of the baby from mechanical ventilator as her mother was known to be having MG. The test result was positive. Therefore, neostigmine treatment (0.01 mg/kg/h) began at 41st hour of hospitalization. The baby's abdomen distention developed at 56th hour of hospitalization. The finding of direct abdomen X-ray was consistent with intestinal perforation [Figure 1]. A colostomy was performed. Neostigmine was stopped as its effects in increasing risk of intestinal perforation were known. Pathology result was consistent with spontaneous intestinal perforation. No serious complication developed afterwards and the patient was extubated on her 19th day of hospitalization. The patient was discharged with full recovery after her general condition improved on the 35th day of hospitalization.

### Access this article online

Website: <a href="http://www.ijmsph.com">http://www.ijmsph.com</a>	Quick Response Code:
DOI: 10.5455/ijmsph.2015.24082014167	

International Journal of Medical Science and Public Health Online 2015. © 2015 Mervan Bekdas. This is an Open Access article distributed under the terms of the Creative Commons Attribution 4.0 International License (<http://creativecommons.org/licenses/by/4.0/>), allowing third parties to copy and redistribute the material in any medium or format and to remix, transform, and build upon the material for any purpose, even commercially, provided the original work is properly cited and states its license.



**Figure 1:** Abdominal radiography of the patient.

## Discussion

The risk of developing neonatal transient MG in babies born to pregnant women with acquired MG whether active or in remission regardless of the presence or absence of the anti-acetylcholine receptor antibodies is demonstrated.<sup>[4]</sup> Clinical symptoms observed in babies born to pregnant women using anticholinesterase agent may be insignificant within first 24 h, but it will not take longer than 72 h for the clinical table to settle down.<sup>[2]</sup>

Neonatal MG, which is a self-limiting disease, tends to become severe if precise diagnosis and respiratory support treatment are not provided. This disease is divided into two types: permanent and transient. The permanent type has a genetic origin and it is observed in babies whose mothers are not having MG.<sup>[5,6]</sup> No clinical symptoms may be present in mothers of some of the babies diagnosed with the transient-type MG, the majority of whom are born to mothers diagnosed with MG, or the mothers' disease may be in remission.<sup>[7,8]</sup> Diagnosis is easy for hypotonic babies whose mothers are diagnosed with MG. However, in cases in which diagnosis is suspicious due to rare observation of MG among other causes of neonatal hypotonia,<sup>[9]</sup> diagnostic tests conducted with neostigmine may be applied. It is possible to obtain the results of this test, which is conducted in an

environment in which the conditions for urgent resuscitation are present, within approximately 15 min. It has been observed that the clinical symptoms of the patient have improved in cases in which results have been obtained.<sup>[4]</sup>

Treatment of the transient neonatal MG includes supporting vital functions and nutritional needs, particularly the respiratory system, until the weakness resolves spontaneously. Twenty percent of the patients have insignificant symptoms; close observation and frequent oral feeding is sufficient for these patients. Clinical symptoms of 80% of them are mild-ranged or severe. Neostigmine is frequently used in their treatment. Neostigmine dosage shall be increased so that the sucking and swallowing functions of the baby meet his/her nutritional needs.<sup>[4]</sup> Neostigmine stops hydrolysis of acetylcholine through bonding with cholinesterases; in addition, it increases peristaltic movements and intraluminal pressure by affecting the intestinal soft muscles due to its muscarinic effects.<sup>[10]</sup> Intestinal perforation after use of neostigmine was found in the two cases in the literature, one in which neostigmine was used and the development of intestinal perforation was related to the use of steroids,<sup>[11]</sup> and the other case in which the development of an anastomotic leak in the patient after hemicolectomy was related to the anticholinesterases used;<sup>[12]</sup> no cases involving children were found.

## Conclusion

We aimed at emphasizing that intestine perforation may be observed in babies diagnosed with neonatal transient MG, particularly when neostigmine is used. Therefore, it is necessary to be careful.

## References

1. Sisman J, Ceri A, Nafday SM. Seronegative neonatal myasthenia gravis in one of the twins. *Indian Pediatr* 2004; 41(9):938–40.
2. Lefvert AK, Osterman PO. Newborn infants to myasthenic mothers: a clinical study and an investigation of acetylcholine receptors antibodies in 17 children. *Neurology (NY)* 1983;33:133–8.
3. Chan KY, Leung FW, Lam HS, Tam YH, To KF, Cheung HM, et al. Immunoregulatory protein profiles of necrotizing enterocolitis versus spontaneous intestinal perforation in preterm infants. *PLoS One* 2012;7:e36977.
4. Papazian O. Transient neonatal myasthenia gravis. *J Child Neurol* 1992;7(2):135–41.
5. Engel AG. Congenital myasthenic syndromes. *J Child Neurol* 1988;3:233–46.
6. Misulis KE, Fenichel GM. Genetic forms of myasthenia gravis. *Pediatr Neurol* 1989;5:205–10.
7. Elias SB, Butler I, Appel SH. Neonatal myasthenia gravis in the infant of a myasthenic mother in remission. *Ann Neurol* 1979;6:72.
8. Verspyck E, Mandelbrot L, Dommergues M, Huon C, Woimant F, Baumann C, et al. Myasthenia gravis with polyhydramnios

- in the fetus of an asymptomatic mother. *Prenat Diagn* 1993;13:539.
9. Laugel V, Cossée M, Matis J, de Saint-Martin A, Echaniz-Laguna A, Mandel JL, et al. Diagnostic approach to neonatal hypotonia: retrospective study on 144 neonates. *Eur J Pediatrics* 2008;167(5):517–23.
  10. Hirst GR, Karandikar SS, Brown G, Slowey H, Beynon J. Colonic anastomotic disruption in the immediate postoperative period. *Int J Colorectal Dis* 2004;19:281–2.
  11. Mariasy Y, Shapiro A, Mitchell TH. Bowel perforation in a patient receiving prednisolone for myasthenia gravis. *Postgrad Med J* 1989;65(764):428–9.
  12. Li Destri G, Scilletta B, Latino R, Di Cataldo A. Myasthenia gravis and intestinal resection: is dehiscence likely to occur? *Min Chir* 2006;61(6):525–8.

**How to cite this article:** Bekdas M, Altunhan H, Göksügür S, Ozturk H, Demircioglu F. Neonatal transient myasthenia gravis and a case with intestinal perforation. *Int J Med Sci Public Health* 2015;4:870-872

**Source of Support:** Nil, **Conflict of Interest:** None declared.